



PATIENT PRESENTING CLINICAL SIGNS

Luna Pupo Luna presented after a severe episode of neck and back stiffness due to hard movements. Owner reports pain on neck and back and patient presented a arched back.
Abnormal PE/Chem/CBC/UA Results: CHEM --- unremarkable

SPECIES

Canine

COMPUTED TOMOGRAPHIC STUDY OF THE NECK

Plain and post contrast studies are available for review.

BREED

Maltese

COMPUTED TOMOGRAPHIC FINDINGS

A large ill-defined right-sided paraxial soft tissue mass, is present within the cervical musculature measuring ~ 7 cm x 3.5 cm x 3 cm. The lesion is predominantly fat attenuating and demonstrates infiltrative and locally aggressive behavior. The mass extends into the vertebral canal at the level of C3-4 resulting in significant extradural mass effect onto the cervical spinal cord and adjacent right-sided nerve root structures. Associated osseous invasion with bone destruction involving the vertebral bodies of the vertebrae C4 and C3 is seen as well. Surrounding regional soft tissue distortion and swelling is present to the right of the midline accentuated dorsally.

SEX

FS

AGE

12yr

COMPUTED TOMOGRAPHIC DIAGNOSIS

- Large infiltrative right paraxial cervical mass with predominantly fatty attenuation and aggressive behavior, extension into the vertebral canal at C3-4, associated osseous invasion of C4 and C3 vertebral structures.

INTERPRETED BY

Nele Eley (Ondreka),
DVM Dr. med. vet.,
DipECVDI

INTERPRETATION OF FINDINGS & FURTHER RECOMMENDATIONS

The imaging features are most consistent with an infiltrative lipomatous neoplasia. Infiltrative lipoma or liposarcoma are considered the primary differentials. The degree of local invasiveness and vertebral involvement as well as the extension into the spinal canal indicate biologically aggressive behavior. Histopathologic diagnosis can be considered to confirm and differentiate infiltrative lipoma from liposarcoma. Complete surgical debulking is not possible based on the CT presentation. Oncology consultation can be considered.

HOSPITAL NAME

Veterinary Image
Center

REFERRING VET

José Diaz Umpierre,
DVM

INVOICE

24907

DATE

05/21/2026



PATIENT

Luna Pupo

SPECIES

Canine

BREED

Maltese

SEX

FS

AGE

12yr

INTERPRETED BY

Nele Eley (Ondreka),
DVM Dr. med. vet.,
DipECVDI

HOSPITAL NAME

Veterinary Image
Center

REFERRING VET

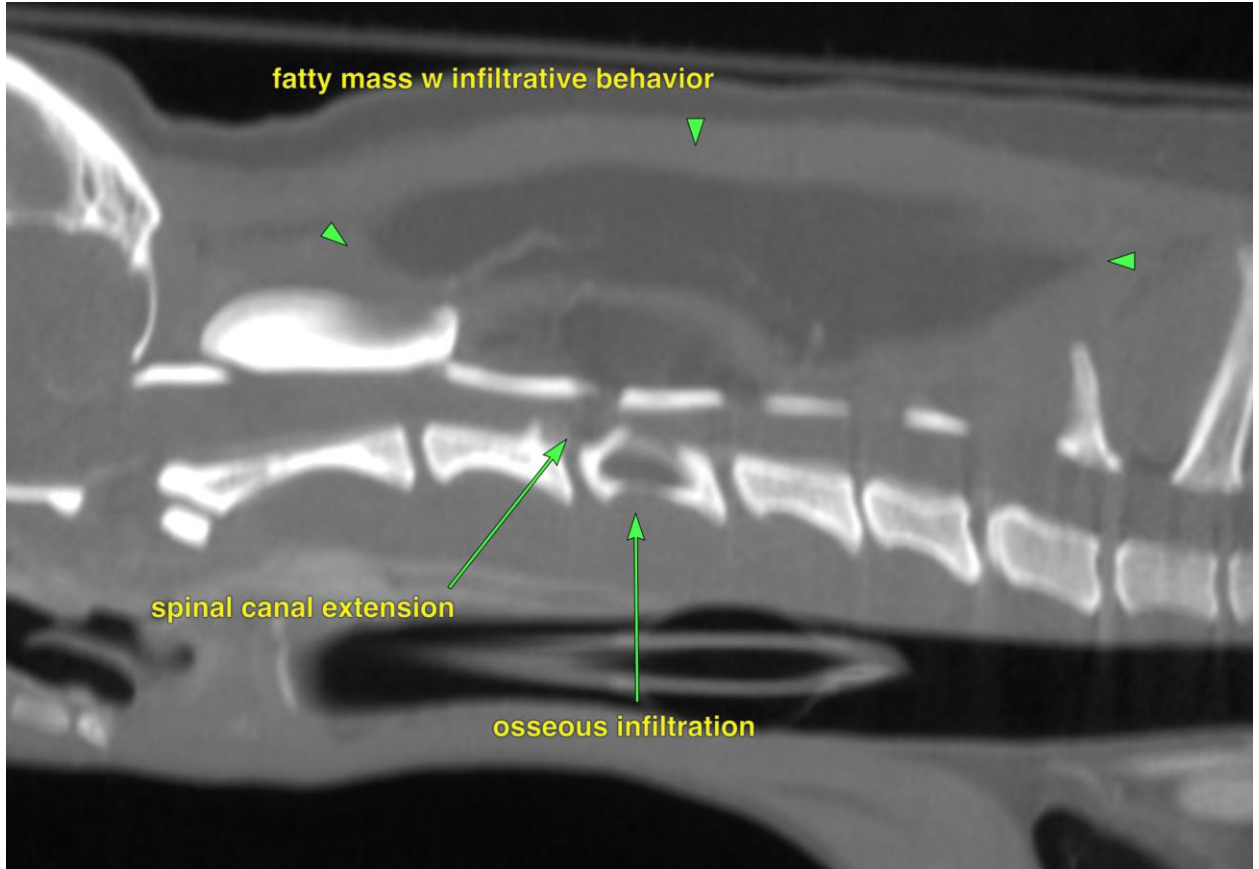
José Diaz Umpierre,
DVM

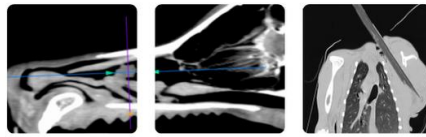
INVOICE

24907

DATE

05/21/2026





PATIENT

Luna Pupo

The information and recommendations provided are based on the images presented by the referring veterinarian. No evaluation can be communicated regarding pathology that was not visible in the image/video clips provided.

SPECIES

Canine

Thank you for this referral. If the clinical or image interpretation does not parallel your findings or if I can be of any further assistance please contact me.

BREED

Maltese

Nele Eley (Ondreka), DVM, Dr. med. vet., DipECVDI
European Specialist in Veterinary Diagnostic Imaging, Cert. Radiology,
Senior lecturer University of Giessen/Germany, Veterinary Faculty, Department of Radiology.
info@sonopath.com

SEX

FS

AGE

12yr

INTERPRETED BY

Nele Eley (Ondreka),
DVM Dr. med. vet.,
DipECVDI

HOSPITAL NAME

Veterinary Image
Center

REFERRING VET

José Diaz Umpierre,
DVM

INVOICE

24907

DATE

05/21/2026